


HAL STEWART, DDS



Systems Based Minimally Invasive Rejuvenation Dentistry

As our population becomes more health conscious, its desire to seek minimally invasive dentistry has increased tremendously over the past 2-3 years. This is a good thing. People don't want their teeth whittled down anymore if they can avoid it. Dr. Michael Schuster often states that what people really "want" is no dentistry!

However, occlusal disease is rampant and the demand for practitioners who can predictably treat this is increasing exponentially. It is the author's opinion, based on what he sees in his office, that at least 85% of the population suffers from some degree of occlusal disease. The resulting symptoms can be tooth hypersensitivity, myofacial pain and tension, and/or temporomandibular discoordination and the subsequent

symptoms associated with that; popping and clicking of the joint(s), pain in the joints, stiffness or ringing in the ear, among others. The signs can be tooth wear, abfractions, gingival recession bone loss, and a decrease in the lower third of a person's facial height.

MINIMALLY INVASIVE REJUVENATION DENTISTRY

Minimally Invasive Rejuvenation Dentistry (MIRD) is a wonderful way to treat occlusal disease and its resulting symptoms and signs while salvaging as much natural tooth structure as possible. It is conservative (often times no prepping is needed); esthetic; predictable; and much more affordable than the traditional full mouth rehabilitations done in porcelain.

SYSTEMS THINKING

"Successful occlusal treatment is dependent on complete harmony of all the passive and active components of a very precise and complex system. It is not possible to have an adequate understanding of occlusion outside of the framework of the stomatognathic system"¹

- Dr. Peter Dawson

The key to MIRD is that it is based upon treating the stomatognathic system as just that, a system. It is this author's opinion that in treating occlusal disease, all of the parts of the system must be addressed. The stomatognathic system is comprised of the following:

- The CNS – Anterior Proprioceptive Guidance
- The Muscles – The muscles of mastication and facial expression. Head, neck, and even shoulder muscles are associated as well
- The Osseous Tissues
- The Soft Tissues- Mucosa, Lips, Gingiva, PDL, etc.
- The Teeth
- The TMJ
- The Airway

In a nutshell, the muscles must be relaxed, the TMJ stabilized, the correct biologic anatomy restored to the individual teeth, and the correct inter-arch relationship (occlusion) re-established.

THE FOUR AXIOMS OF MINIMALLY INVASIVE REJUVENATION DENTISTRY

The term "Axiom" is described as follows, and the author is paraphrasing

from *Webster's New World Dictionary, College Edition*: "An established principle, or law that is self evident."

The self evidence stated here was first introduced by Dr. Robert Lee in 1990.³ Since these axioms were based upon the findings of completely healthy and asymptomatic stomatognathic systems, they received immediate acceptance in the community of esthetic dentistry.

The early acceptance had continued to grow among an ever-increasing number of dentists who maintain these axioms in their practices and in functional and esthetic presentations.^{2,4-6} According to Lee, the ideal stomatognathic system shares three commonalities:

1. Stable condylar position – superior, anterior, and medially braced
2. Proper tooth form, as it occurs in nature, with unaltered anatomy
3. Adequate vertical dimension of occlusion that allows the correct vertical and horizontal overbite and proper anterior-posterior relationship of the maxillary and mandibular teeth

A fourth axiom has been identified in recent years with the ever-increasing awareness of obstructive sleep apnea and the development of cone beam computed tomography. This fourth axiom is:

4. The airway

When these axioms are present in a masticatory system, we see neuromuscular release, combined with the reduced force on the dentition due to a more vertical chewing pattern and true anterior proprioceptive guidance re-established. This results

in the preservation of individual teeth and maximum facial esthetics. It also allows conservative restorations, since the shearing forces are minimized or eliminated altogether. We are also observing and increase in the minimal restricted area of the airway. While these observations are at this time, anecdotal, they are promising and more research must be done in this area.

The functional goal of MIRD is to maximize anterior guidance and to verticalize the posterior segment with the normal physiologic position of the condyles in their most stable centric relation (CR).² It has been documented by Williamson that the activity of the masseter and temporalis elevating muscles can be reduced only when the posterior disclusion is obtained by appropriate proprioceptive anterior guidance.⁷ When proprioceptive anterior guidance is present, the posterior segment is verticalized, thereby eliminating eccentric contacts on cusp tips and incisal edges. Williamson also states that it is not the contact of the canines that decreases the activity of the temporalis and masseter muscles, because in true proprioceptive anterior guidance the canines do not contact at all. Rather, it is the elimination of posterior eccentric contacts that results from the proprioceptive anterior guidance.⁷

Adherence to these three axioms and awareness of the fourth (airway) allowed the author to develop a minimally invasive rejuvenation practice on his patients. The result was not only a dramatic improvement in the function and appearance of the dentition, but also the treatment eliminated headaches and myofacial pain and tension. The relaxation of the facial muscles becomes evident in the relaxed general appearance

of the patient's face. Many patients claim that they look and feel at least five years younger.

CASE REPORT

CLINICAL EXAMINATION AND DIAGNOSIS: SUBJECTIVE AND OBJECTIVE FINDINGS

A 52-year old white female patient (Figures 1 and 2) presented with the following complaint: "I do not like the appearance of my smile. My teeth are wearing down and my face is getting shorter. I get headaches frequently and have tension in my face and neck constantly" The patient was living a healthy life-style, was taking no medication, and the medical history was unremarkable. A thorough preclinical interview revealed that the patient suffered from chronic headaches, myofacial pain, and tension. Dental records were obtained and a comprehensive clinical examination was performed. The full periodontal evaluation included probing depths, plaque indices, bleeding indices, head and neck muscle examination, oral cancer examination, occlusal analysis, TMJ evaluation, and a tooth-by-tooth examination. Facial dimension analysis was completed as well. The patient was sent to an imaging center for cone beam computed tomography images, and a subsequent airway and TMJ radiology report was obtained from Dr. David Hatcher (Beam Readers, Inc.)

The patient's oral environment contained several dental restorations consisting of the following:

- Crowns on #s 13, 14, 18 and 31
- Composites on #s 4, 5, 20, and 30



Figure 1a and 1b. Full face views at presentation. A 52-year female patient presented unhappy with her smile, chronic facial muscle tension, and headaches.

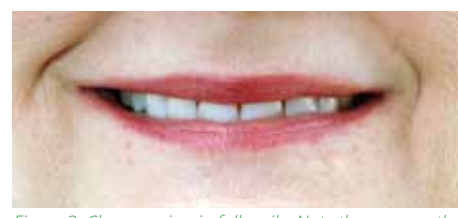
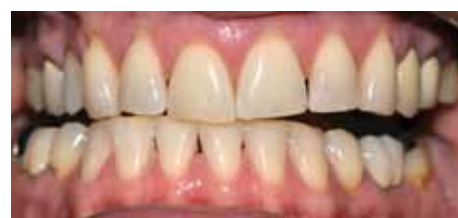
Figure 2. Close-up view in full smile. Note the wear on the maxillary anterior teeth and the uneven incisal edges.

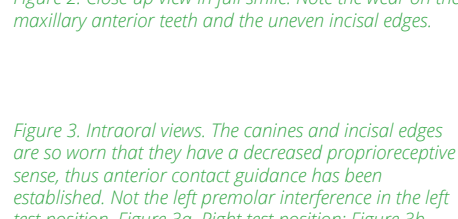
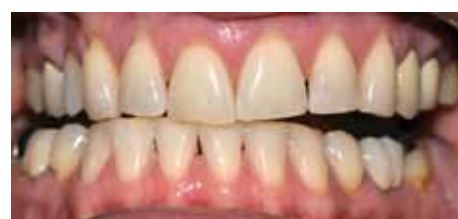

Figure 3. Intraoral views. The canines and incisal edges are so worn that they have a decreased proprioceptive sense, thus anterior contact guidance has been established. Note the left premolar interference in the left test position. Figure 3a. Right test position; Figure 3b. Protrusive test position; Figure 3c. Left test position

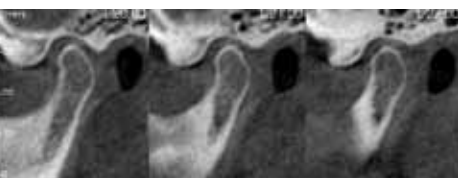
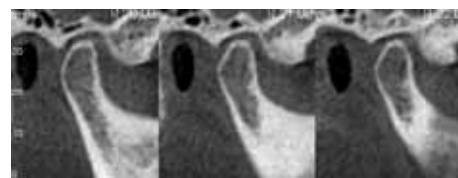
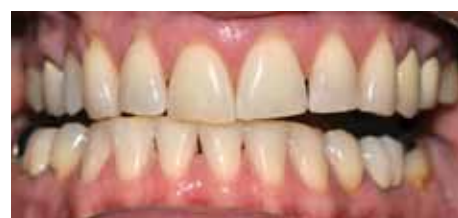
Figure 4. Pretreatment CBCT images of the condyles reveal the position, down and posterior of the distracted condyles during maximum intercuspation.

At the time of examination, her mouth was caries free. The periodontal health was excellent; plaque and bleeding absence was over 90%. Examination of the dentition revealed generalized moderate to severe enamel wear. There was a reduction in over-jet; anterior proprioceptive guidance was absent and the patient was functioning with anterior con-

tact guidance (Figure 3). No popping, clicking, or joint crepitus noises were present. The temporomandibular joint was not diseased or deranged; however, through CBCT imaging, it was discovered that her habitual occlusion was distracting the condyles out of their SAM position downward and posteriorly (Figure 4). The overall joint anatomy was normal.

DIAGNOSIS/ASSESSMENT

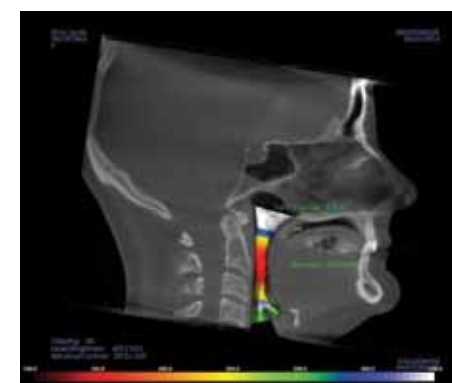
Although there were no joint noises or joint pain, it became apparent that the enamel wear and subsequent myofacial symptoms resulted from a mandible-to-cranial base discrepancy, most likely caused, or at least exacerbated by, a malocclusion. The lack of anterior proprioceptive guidance and the resulting posterior eccentric interferences lead to muscle hyperactivity, resulting in enamel wear and facial muscle tension, as well as distraction of the condyles during maximum intercuspation. Fortunately, the patient did not suffer from a compromised airway, as the airway study showed a minimal restricted area of 153mm². (Figure 5)

While airway was not an issue in this particular case, the author is observing time and time again that stabilizing the condyles and relaxing the muscles can result in an increase in the airway. (Figures 6,7) These are CBCTs of one of the author's patients. Figure 6 shows a pre-treatment minimally restricted area of 43.7mm². Figure 7 shows a post-treatment minimally restricted area of 147.7mm². This is over a 300% increase in the minimally restricted area.

INITIAL TREATMENT PLAN

The initial treatment plan was to achieve an optimal stable condylar position, using a therapeutic maxillary condylar centering orthotic (C2O). (Figure 8). The C2O is a condylar CR repositioning splint. When worn consistently throughout 24-hour periods and adjusted regularly, it will allow the mandibular positioning muscles to relocate the condyles into the optimal stable condylar position (OSCP).

The patient wore the splint for a period of six weeks to allow full seating of



Clockwise from top:

Figure 5. Pretreatment CBCT images and airway study show a patent airway with a minimally restricted area of 153mm².

Figure 6. Pretreatment CBCT images and airway study show a restricted airway in another patient of Dr. Stewart's. The minimal restricted area is 43.7 mm².

Figure 7. Post treatment CBCT image and airway study of the same patient in figure 6 reveal an increase in the minimally restricted area of over 300%, from 43.7mm² to 147.7mm².

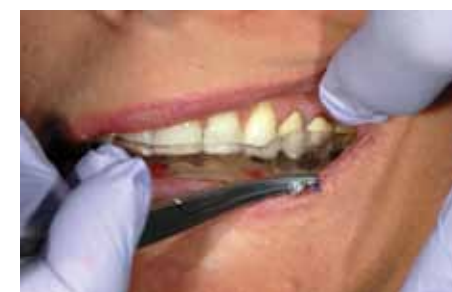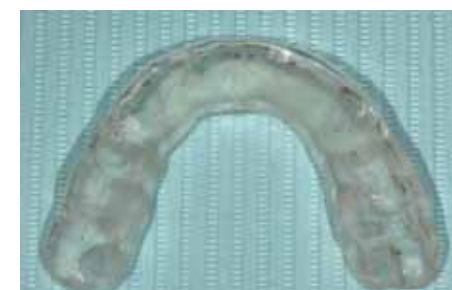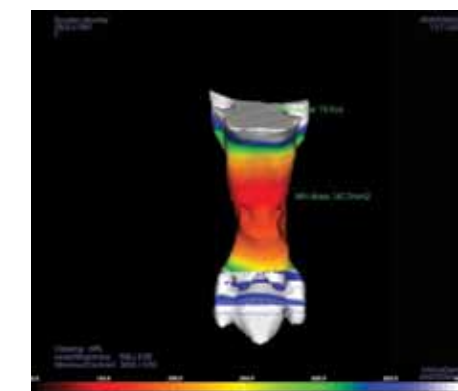


Figure 8. View of the condylar centering orthotic (C2O). Figure 8a. C2O splint; Figure 8b. Adjusting the splint; Figure 8c. Patient wearing the C2O.

the condyles, presenting for regular adjustments. OSCP was verified, using the AD2 MCP (measures condylar displacement) instrument (Advanced Dental Designs Inc., CA). (Figure 9 and 10). A hinge axis recording was taken along with joint tracings and Bennett movements, and the data were entered into the AD2 articulator. The maxillary diagnostic model was mounted at the hinge axis position to accurately reflect any change in the vertical dimension of occlusion.

The pretreatment and post-orthotic occlusions and mounted study models were compared (Figures 11 and 12). It was discovered by observing the hinge-axis optimal stable condylar position models that avoidance patterns by the patient had created a fulcrum effect thereby distracting the condyles down and posterior in order to achieve maximum intercuspation. This 'fulcrum effect' resulted in occlusal posterior avoidance patterns, as the patient was posturing the mandible forward to avoid the second molar contacts. This posturing resulted in the hyperactivity of the masseter, temporalis, and lateral pterygoid muscles, and the subsequent attrition of the enamel.

By tracking condylar movement from centric relation to centric occlusion from the hinge axis position, the author was able to predictably alter the VDO in a scientific manner.⁷ The vertical dimension, upon observation of the hinge axis study models, could be adequately restored at 17.8mm, 18.8mm, or 19.8 mm or anywhere within this range. Three vertical dimension jigs were made on the hinge axis mounted models and the patient was allowed to take these home for the weekend to determine which VDO was the most comfortable and which resulted in the most pleasing facial esthetics. Upon observation of






Figure 9a 9b, and 9c. Three consecutive open cr bites, each taken a week apart, are used to determine optimal stable condylar position has been achieved.


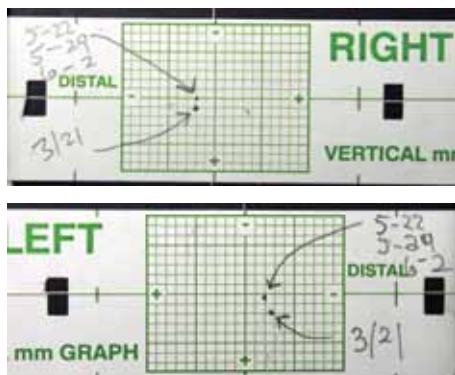


Figure 11. Pretreatment mounted study models.

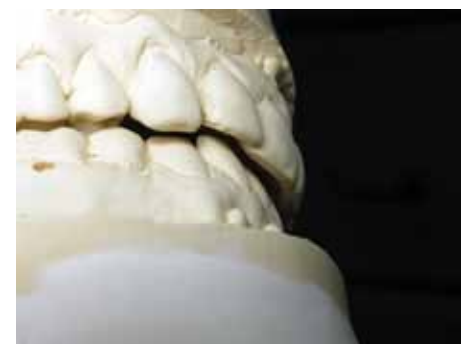

Figure 12. Post orthotic mounted, hinge axis mounted study models at optimal stable condylar position. Notice the anterior open bite resulting from proper seating of the joint which reveals the posterior interferences.

Left:

Figure 10. The lower dots on each graph represent the pretreatment condylar position. The graph paper from the AD2 MCP instrumentation shows the right condyle moved (top) up primarily with some anterior repositioning, while the left condyle moved upward and forward (bottom). The upper dots in both represent the 3 consecutive bites illustrated in figure 9. The upper dots are superimposed upon one another indicating that the condyles are seated and no longer moving.

her photographs (Figure 13) and discussion of her comfort, it was decided to restore the case at the 17.8mm dimension, as it provided the necessary space to restore the lost enamel and anatomy of the anterior and posterior teeth, and it was situated comfortably within the averages of Lee's human biologic model.

This patient had only a moderate amount of dental restorations. Most teeth were virgin and had no caries. The teeth were suffering primarily from the occlusal disease of attrition. Therefore, a conservative approach with little to no iatrogenic removal of enamel was pursued to restore the lost tooth structure. Three existing crowns would be replaced as well.

The lengths of teeth in an average dentition, common to all masticatory systems, have been established in the literature;⁹ they were determined by Lee through observation and documentation of healthy stomatognathic systems:¹⁰

- Maxillary central incisors: 11mm – 13mm, with an average of 12mm
- Maxillary canines: 11mm – 13mm, with an average of 12mm
- Mandibular central incisors: 9mm – 12mm, with an average of 10mm
- Mandibular canines: 11mm – 15mm, with an average of 12mm
- Vertical dimension of occlusion, or VDO (as measured from the cej of the maxillary central incisor to that of the opposing mandibular central incisor): 16mm - 20mm with an average of 18mm
- Vertical overbite: 3mm

- Horizontal overbite, or over jet: 2mm

These figures are average and serve as dependable markers, but they should not be construed as 'automatic' in the restoration of every dentition.

With Lee's human biologic model serving as a guideline, and the final VDO decided upon a thorough evaluation of the post-C2O hinge axis mounted study models was pursued and a complete diagnostic wax up was completed.

RESTORATIVE TREATMENT: ADDITIVE CORONOPLASTY (25 TEETH); CROWNS (3 TEETH)

Following completion of the diagnostic wax-up, the desired vertical dimension of 17.8mm a clear polyvinyl siloxane stint was fabricated over each wax-up. These stints would be used to transfer the newly formed biologic tooth morphology from the wax-up to the mouth. The scope of this article does not allow for the specifics of the technique to be illustrated.

The anterior teeth were restored first. No teeth were prepped and the positive coronoplasties were completed with no anesthesia needed. The centric stops and test positions were verified on the anterior teeth prior to moving to the posterior teeth. (Figure 14)

Upon completion of the anterior teeth, the posterior positive coronoplasties were completed in the following order: left mandibular posteriors, right mandibular posteriors, left maxillary posteriors, right maxillary posteriors. Once these were completed, the three crowns were completed and rejuvenation provisionals fabri-



Figure 13a,b,c. Vertical Dimension jigs in place. From top: 17.88mm; 18.8mm; 19.8mm.

cated from the diagnostic wax up.

POST-TREATMENT TEST POSITIONS

The post-treatment test positions show anterior disclusion in eccentric movements, evidencing the restoration of the anterior proprioceptive guidance (Figure 15). As the occlusion is verticalized and the anterior proprioceptive guidance is restored to the chewing system, the condensing and shearing forces on individual teeth are minimized, permitting the conservative treatment option illustrated in this case with very minimal enamel preparation.

The increase in the length of the teeth, along with the increased vertical dimension of occlusion, created a result that was beautiful and functional. The patient reported that the myofacial tension and the headaches were eliminated completely. This well-being was the result of a favorable neuromuscular relaxation of the facial and neck muscles. The patient was also pleased with the increased tooth length and the appearance of her new smile (Figures 16 and 17).

CONCLUSION

This patient's smile could have been improved by cosmetic dentistry alone. But simply performing cosmetic dentistry in this case would, in the author's opinion, have been a 'Band-Aid' approach to treatment, addressing the effect (enamel attrition), but not the cause (mandible-to-cranial-base-created-malocclusion). Cosmetic dentistry alone would have done nothing to improve the patient's myofacial pain, headaches, among other symptoms. And the wear on the patient's opposing teeth would have been exacerbated by any type of porcelain restorations.

The traditional full mouth restora-

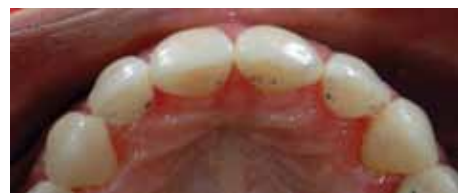
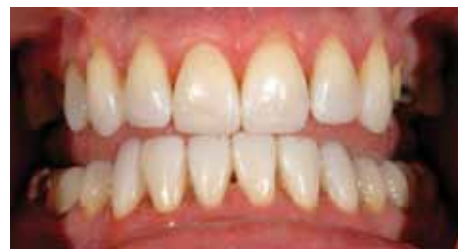
Figure 14. Anterior teeth restored in composite resin (top) with no anesthesia and no prepping. The occlusion was refined and centric stops verified (bottom)

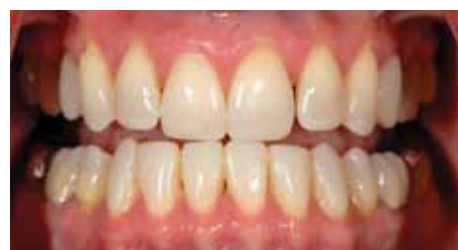
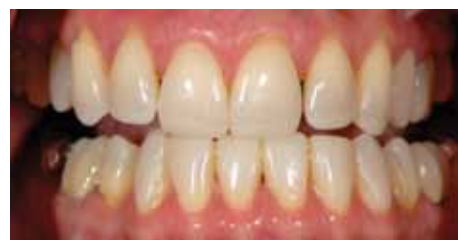
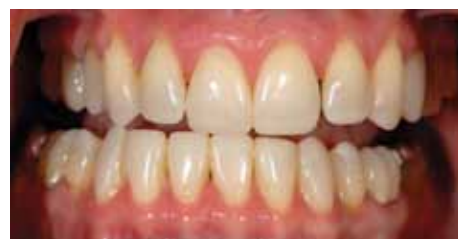Figure 15. All the teeth restored in composite with the exception of #3, 13,14 which were restored with porcelain crowns (E-Max). Comparison of the test positions with the pre-operative occlusion. Right test position (top); Protrusive test position (center); Left test position (bottom).

tive treatment would have consisted of crowns, veneers, and onlays. All of these require aggressive tooth preparation.

By applying the four axioms of Minimally Invasive Rejuvenation

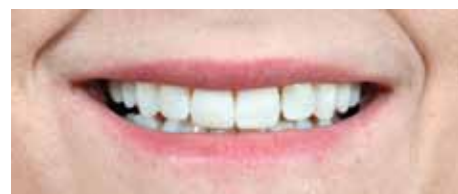
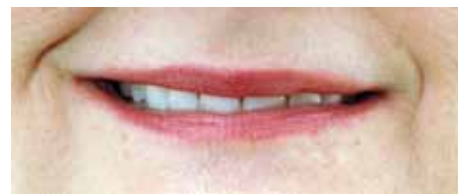
Figure 16: Pretreatment (top) and post treatment (bottom) photos of the patients smile. Note the increase in lip fullness.



Figure 17: Pretreatment (top) and post treatment (bottom) portrait photos. Note the over all relaxed appearance, opening of the eyes and fuller smile.

Dentistry an accurate diagnosis and a minimally invasive, conservative, and affordable treatment plan was implemented and completed. The esthetic goals of the patient were achieved, while improving the patient's health, comfort, and well-being.

REFERENCES

1. Dawson, Peter. In: Dawson, P. TMJ And Occlusal Therapy, Quintessence
2. Stewart H. Conservative full mouth rehabilitation using the principles of bioesthetic dentistry. Contemp Esthet 2006;10(9):46-56.
3. Lee RL. Esthetics and its relationship to function. In: Rufenach, CR. Fundamentals of Esthetics. Carol Stream, IL: Quintessence; 1990, Chapter 9.
4. Hunt K. Bioesthetics: The study of beauty in life. Dent Today 1996;Jan:48-55.
5. Stewart H. Lasting natural beauty: The principles of bioesthetic dentistry. Contemp Esthet and Restor Pract 2005;9(9):52-53.
6. Dumont T. Clinical dentistry: Bioesthetics. Private Pract 2001;2(8):1-3.
7. 1983Williams, E.H. and Lundquist, D.O. Anterior guidance: Its Effects On Electro-myographic Activity Of The Temporal and Masseter Muscles. Journal of Prosthetic Dentistry 49(6): 816-823,
8. Gittleson GL. Understanding occlusion is key to implant success, Art of Articulation. 2003;1(1):1-2.
9. Liner HA. Tooth Carving Manual. New York, NY: Columbia Dentoform Co., A Syntex Co. 1949:5.
10. Hunt K, Turk M. Correlation of the AACD accreditation criteria and the human biologic model. J Cosmet Dent 2005;21(3):94-105.



Dr. Hal Stewart is a 1989 graduate of Baylor Dental College. He is co-founder and co-director of The Texas Center for Occlusal Studies and Minimally Invasive Dentistry (www.txcos.com).

Dr. Stewart has studied at the Pankey Institute, and he completed extensive cosmetic training at LVI. He is a Level 4 Graduate of Orognathic Bioesthetics International.

A member in the AACD for the past 20 years, Dr. Stewart served as president of the Texas Academy of Cosmetic Dentistry. He is also a mentor and faculty member of the Schuster Center in Scottsdale, AZ. He also lectures extensively world wide for Ultradent.

Dr. Stewart practices Minimally Invasive Rejuvenation Dentistry in Flower Mound, TX, and can be reached at :

6011 Morriss Road, Suite #200
 Flower Mound, TX 75028
 Tel: 972-874-3957
 e-mail: hal.stewart@verizon.net
 website: www.halstewart.com
 The Texas Center: www.txcos.com